

Small and large MRI-visible perivascular spaces in the basal ganglia of Parkinson's disease patients

Stephanie A. Berberian¹; Joel Ramirez¹; David P. Breen²; Tiago A. Mestre³; Connie Marras⁴; Donna Kwan⁵; Sean Symons⁶; Mario Masellis⁷; Sandra E. Black⁷; Anthony E. Lang⁴

¹Dr. Sandra Black Centre for Brain Resilience and Recovery, Hurvitz Brain Sciences Program, Sunnybrook Research Institute, University of Toronto; ²Centre for Clinical Brain Sciences, University of Edinburgh; Anne Rowling Regenerative Neurology Clinic, University of Edinburgh; Usher Institute of Population Health Sciences and Informatics, University of Edinburgh; ³Department of Medicine, Division of Neurology, Ottawa Hospital Research Institute, University of Ottawa; ⁴Edmond J. Safra Program in Parkinson's Disease and the Morton and Gloria Shulman Movement Disorders Clinic, Toronto Western Hospital; ⁵Queen's University, Centre for Neuroscience Studies; ⁶Department of Medical Imaging, University of Toronto, Sunnybrook Health Sciences Centre; ⁷Department of Medicine (Neurology), Sunnybrook Health Sciences Centre and University of Toronto

INTRODUCTION

Perivascular spaces (PVS) are fluid-filled spaces surrounding the cerebral vasculature.¹ There is evidence to suggest that pathologically dilated PVS that become visible on MRI may be indicative of hypertensive arteriopathy and glymphatic clearance dysfunction.^{2,3} Additionally, dilated PVS burden in the basal ganglia region (BG-PVS) have been implicated as potential indicators for the progression of motor disability,^{4,5} and cognitive decline⁶⁻⁸ in PD. Evidence suggests that there are pathophysiological differences between **large (> 3mm diameter) and small (≤ 3mm) PVS**,^{9,10} although not specifically demonstrated in PD. The purpose of this study is to examine associations between quantitative measures of BG-PVS, and motor and non-motor features assessed using the **Movement Disorder Society Unified Parkinson's Disease Rating Scale (MDS-UPDRS)** Parts I-IV.¹¹ Below is a brief overview of each Part:

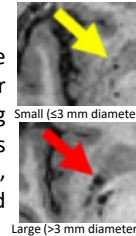
Part I	Part II
Daily Non-Motor Symptoms	Daily Motor Symptoms
Cognitive Impairment	Speech
Fatigue	Chewing & Swallowing
Depressed Mood	Hygiene
Part III	Part IV
Motor Examination	Motor Complications
Gait	Dyskinesias
Postural Stability	Dystonia
Resting Tremor	Motor Fluctuations

METHODS

Study participants were 139 PD patients from the Ontario Neurodegenerative Disease Research Initiative (ONDRI).¹² PD motor and non-motor symptom severity was assessed using the MDS-UPDRS Parts I-IV. Cognition was assessed using the Montreal Cognitive Assessment tool (MoCA).¹³ Using the ONDRI neuroimaging quantification method, 3T brain MRI was used to quantify periventricular and deep white matter hyperintensities (p/dWMH), lacunes, and dilated PVS.¹⁴ BG-PVS were delineated and used to classify study participants into two groups: small BG-PVS (≤ 3mm diameter) and large BG-PVS (> 3mm diameter).

Statistical Analysis:

Partial Spearman's correlation and negative binomial regression models adjusted for multiple comparisons using Benjamini-Hochberg false discovery rate (FDR). All analyses accounted for age, sex, education, HbA1C, cholesterol, systolic BP, smoking, lacunes, and head-size adjusted WMH.



DISCUSSION

These results suggest that small BG-PVS in PD patients may impact the motor and non-motor of daily living such as fatigue and speech whereas large BG-PVS may impact the motor symptoms and complications from PD such as gait and dyskinesias.

The precise etiology of small BG-PVS, specifically in PD, may not be in line with current theories that have been proposed of hypertensive arteriopathy. Some insight can be drawn from the correlation between small BG-PVS and pWMH. This finding suggests that global cerebral small vessel disease severity, indicated by pWMH, and smaller dilated PVS in the striatum may share similar etiology. In contrast, large BG-PVS may be more clinically relevant to PD neurodegenerative processes occurring in the striatum, which is congruent with the current study's association with large BG-PVS and motor symptoms/complications, and the lack of correlation with other small vessel disease markers.

RESULTS

Small BG-PVS (≤3 mm in diameter)

FDR-adjusted negative binomial regression revealed an association with small BG-PVS counts and the MDS-UPDRS Part I ($p < 0.01$, 95% confidence interval: 0.005, 0.023) and Part II ($p < 0.01$, 95% C.I.: 0.004, 0.023).

Large BG-PVS (>3 mm in diameter)

Similar analysis as above, revealed an association with large BG-PVS counts and the MDS-UPDRS Part III ($p < 0.0001$, 95% C.I.: 0.012, 0.027) and Part IV ($p < 0.001$, 95% C.I.: 0.015, 0.05).

CONCLUSION

The main finding of this study was that there is a differential association between large and small BG-PVS in PD patients. Specifically, a higher burden of small BG-PVS negatively impacts motor and non-motor aspects of experiences in daily living, whereas large BG-PVS are more likely to impact the motor symptoms and complications from PD. These findings were independent of the basic demographic variables and vascular risk factors that are commonly associated with PVS and other imaging markers of cerebral small vessel disease.

Additional Findings

Partial Spearman's correlation showed that small BG-PVS were correlated with pWMH ($\rho=0.26$, $p=0.015$)

References

¹Rasmussen et al., (2018) *Lancet Neurol.* ²Brown et al., (2018) *Cardiovasc. Res.* ³Charidimou et al., (2018) *Neurology* ⁴Chung et al., (2021) *Neurology* ⁵Shen et al., (2021) *Parkinson's Disease* ⁶Park et al., (2019) *Movement Disorders* ⁷Chen et al., (2021) *Parkinsonism and Related Disorders* ⁸Shibata et al., (2019) *Clinical Neurology and Neurosurgery* ⁹Gutierrez et al., (2017) *AJNR* ¹⁰Ding et al., (2017) *JAMA Neurol.* ¹¹Goetz et al., (2015) *Movement Disorders* ¹²Farhan et al., (2017) *Can J Neurol Sci.* ¹³Ziad et al., (2005) *J Am Geriatr Soc.* ¹⁴Ramirez (2020) *Frontiers Neurology*

Funding for this Project was Provided by:

